IMAGING PERFORMED BY

svsmobileimaging.com 309 - 737 - 3070

SVS IMAGING

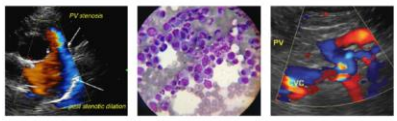

SonoPath

Clinical Sonography & Telecytology

EDUCATIONAL TELECONSULTATION SERVICES™

1-800-838-4268 info@sonopath.com SonoPath.com

PATIENT

Lucy Kieffer

SPECIES

Canine

BREED

Chinese Crested

SEX

Female Spayed

AGE

14 years

WEIGHT

10.5lbs

INTERPRETED BY

Maggie Machen Lamy, DVM, DACVIM (Cardiology)

IMAGING PERFORMED BY

Amy Mayhew, LVT

HOSPITAL NAME

SVS Imaging MI

REFERRING VET

Pincrest AH

INVOICE

30078

DATE

4/5/23

PRESENTING CLINICAL SIGNS

History: Recheck echo – performed at MSU 3-4 years ago. Grade 3/6 heart murmur. Intermittent coughing.

ECHOCARDIOGRAM FINDINGS

2D, m-mode, color flow and doppler imaging is available. Diffuse thickening of mitral valve leaflets (anterior>posterior) with minimal prolapse into the left atrial lumen. Moderate eccentric mitral regurgitation with moderate left atrial dilation. Normal MR velocity. No LV dilation with adequate myocardial function. The tricuspid valve appears thickened with marked prolapse and a ruptured chordae tendineae visualized. Moderate tricuspid regurgitation. Velocity consistent with moderate pulmonary hypertension. Moderate RA and RV enlargement. Mild MPA and branch dilation. The pulmonic and aortic valves are normal in morphology and mobility. Normal pulmonic and aortic outflow velocities. No aortic and trace pulmonic insufficiency. No pericardial or pleural effusion noted. No cardiac tumors observed.

CARDIAC CHART

CANINE CARDIAC PARAMETERS	MR VMAX (m/s)	TR VMAX (m/s)	LA/AO (Boon method)	LA/AO (Heart Base; Swe)	FS (%)	EF (%)	EPSS (cm)
NORMAL PARAMETER	4.5-5.5	<2.7	1.3	<1.6	28-40	40-100	<0.6
PATIENT	5.3	3.9	NM	1.7	40	76	NM
CANINE CARDIAC PARAMETERS	**HR** (BPM)	**AV VMAX** (m/s)	**PV MAX** (m/s)	**BODY WEIGHT** (kg)	**LA** 2D short axis Base view (cm)	**LVIDd** Avg; 2D and m-mode short axis (cm)	**LVIDs** Avg; 2D and m-mode short axis (cm)
NORMAL PARAMETER	50-100	0.7-1.7	0.7-1.6	BELOW	BELOW	BELOW	BELOW
PATIENT	82	1.4	0.8	4.7	1.9	2.1	1.3
*Normal chamber parameters expressed as a mean value (SD)				3	1.27 (5.3)	2.46 (2.46)	1.36 (5.5)
BODY WEIGHT DEPENDENT PARAMETERS				5	1.40 (4.5)	2.74 (5.2)	1.60 (4.7)
**Note: All measurements based upon multi-modal images and methods. An average value is reported.*				10	1.50 (3.8)	3.27 (3.5)	2.06 (3.1)
				15	1.83 (2.0)	3.71 (2.4)	2.43 (2.1)
				20	2.02 (1.9)	4.14 (2.2)	2.80 (2.0)
Adapted from June Boon, Veterinary Echocardiography, 1998				25	2.18 (2.4)	4.48 (2.9)	3.10 (2.5)
Rishniw M and Hollis NE, J Vet Intern Med 2000; 14:429-435				30	2.33 (3.3)	4.83 (3.9)	3.39 (3.4)
Hansson et al, Vet Rad and Ultrasound 2002				35	2.48 (4.3)	5.17 (5.0)	3.69 (4.5)
Bonagura et al. Echocardiography: principles of interpretation, Vet Clin North Am 15:1177, 1995				40	2.62 (5.2)	5.48 (6.1)	3.96 (5.4)
				50	2.88 (7.1)	6.07 (8.3)	4.46 (7.4)

INTERPRETATION OF THE FINDINGS & FURTHER RECOMMENDATIONS

Chronic degenerative valve disease causing moderate mitral and tricuspid regurgitation. While the left heart is only mildly enlarged, the right heart appearance is of greater concern. The tricuspid valve is significantly abnormal with suspicion for a ruptured chordae tendineae. This is extremely uncommon to see, particularly in a stable dog. Moderate pulmonary hypertension is noted, likely secondary to a reported chronic cough (although chronic history is not provided). No additional issues are identified.

Given these findings, recommend Sildenafil on Pimobendan going forward. This is for general cardiac support, given the unusual nature of the findings. The patient only has a mild cough

PATIENT
Lucy Kieffer

SPECIES
Canine

BREED
Chinese Crested

SEX
Female Spayed

AGE
14 years

WEIGHT
10.5lbs

INTERPRETED BY
Maggie Machen Lamy, DVM, DACVIM (Cardiology)

IMAGING PERFORMED BY
Amy Mayhew, LVT

HOSPITAL NAME
SVS Imaging MI

REFERRING VET
Pincrest AH

INVOICE
30078

DATE
4/5/23

documented in the history, which may warrant further treatment, such as Hydrocodone. Baseline chest radiographs are recommended depending on chronicity and frequency of the symptoms. It is important to note that Sildenafil does not directly address the cough; rather this lowers pulmonary pressures to avoid clinical signs such as exertional syncope.

Assessment of progression in the future will help predict long term outcome; however, prognosis is guarded at this stage (B2).

Omega fatty acid supplementation and mild salt restriction may also be of some long-term benefit. Monitor for development of a progressive cough, labored breathing, exercise intolerance or collapse episodes.

Once on the medications for 3-5 days, anesthetic risk is considered moderately elevated. Cardiac protective drug choices (opioid/benzodiazepine premedication, Propofol or alfaxalone induction, iso or sevo gas) are recommended. Monitor for arrhythmias, hypotension, and hypoxia both intra and post-operatively and intervene as necessary. Judicious IV fluid rates are recommended to avoid fluid overload. Avoid heart rate stimulating drugs such as atropine unless clinically indicated.

PLAN

Baseline BP. Institute Sildenafil 1-2mg/kg PO q12h. Institute Pimobendan 0.3mg/kg PO q12h. Further address the cough using Hydrocodone, etc. as discussed.

Recommend monitor for progression with a recheck echocardiogram in 6 months.

IMAGES

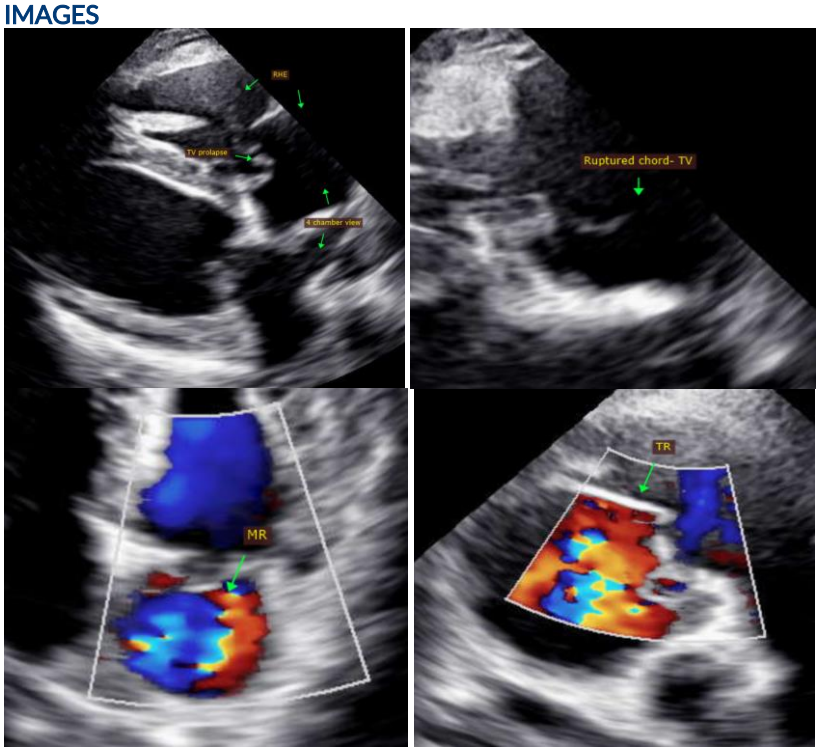

IMAGING PERFORMED BY

svsmobileimaging.com 309 - 737 - 3070

SVS IMAGING

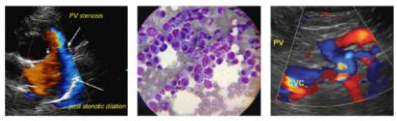

SonoPath

Clinical Sonography & Telecytology

EDUCATIONAL TELECONSULTATION SERVICES™

1-800-838-4268 info@sonopath.com SonoPath.com

PATIENT

Lucy Kieffer

SPECIES

Canine

BREED

Chinese Crested

SEX

Female Spayed

AGE

14 years

WEIGHT

10.5lbs

INTERPRETED BY

Maggie Machen Lamy, DVM, DACVIM (Cardiology)

IMAGING PERFORMED BY

Amy Mayhew, LVT

HOSPITAL NAME

SVS Imaging MI

REFERRING VET

Pincrest AH

INVOICE

30078

DATE

4/5/23

The information and recommendations provided are based on the images presented by the referring veterinarian. No evaluation can be communicated regarding pathology that was not visible in the image/video clips provided.

Thank you for this referral. If the clinical or image interpretation does not parallel your findings or if I can be of any further assistance, please contact me.

Maggie Machen Lamy, DVM
Diplomate of the American College of Veterinary Internal Medicine (Cardiology)
info@sonopath.com